Original Case Examples in Psychiatry

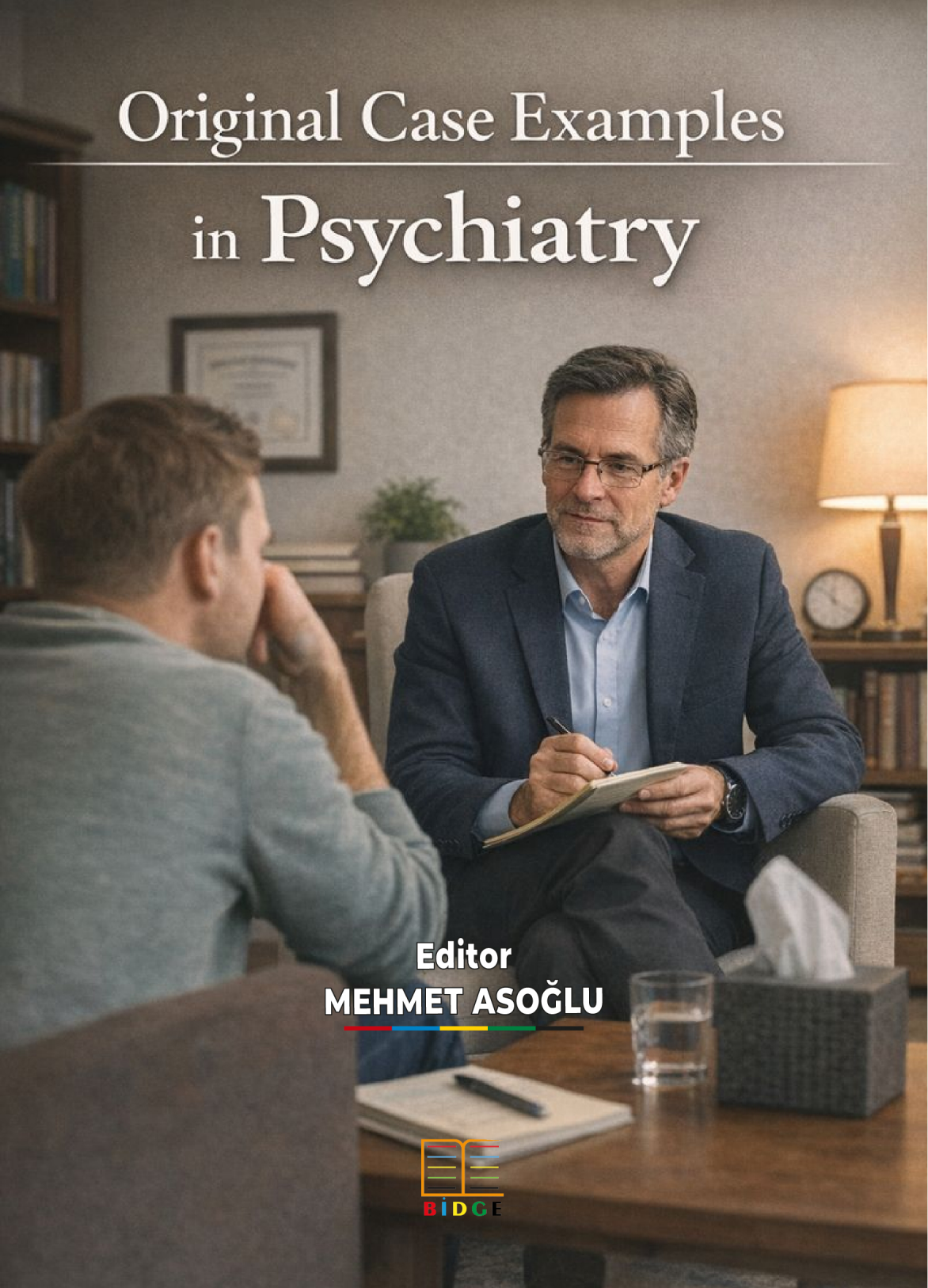

Editor
MEHMET ASOĞLU

BİDGE

BİDGE Yayınları

Original Case Examples in Psychiatry

Editör: MEHMET ASOĞLU

ISBN: 978-625-5474-16-2

1. Baskı
Sayfa Düzeni: Gözde YÜCEL
Yayınlama Tarihi: 2025-12-25
BİDGE Yayınları

Bu eserin bütün hakları saklıdır. Kaynak gösterilerek tanıtım için yapılacak kısa alıntılar dışında yayıncının ve editörün yazılı izni olmaksızın hiçbir yolla çoğaltılamaz.

Sertifika No: 71374
Yayın hakları © BİDGE Yayınları
www.bidgeyayinlari.com.tr - bidgeyayinlari@gmail.com
Krc Bilişim Ticaret ve Organizasyon Ltd. Şti.
Güzeltepe Mahallesi Abidin Daver Sokak Sefer Apartmanı No: 7/9 Çankaya / Ankara

PREFACE

Psychiatric practice often follows well-established diagnostic frameworks and treatment algorithms; however, clinicians are occasionally confronted with rare presentations or atypical clinical courses that challenge routine assumptions. Such cases are valuable not merely because they are unusual, but because they sharpen differential diagnostic thinking, illuminate real-world decision-making, and encourage a careful reconsideration of evidence within the complexity of everyday clinical care.

This book brings together three case reports with the aim of enhancing clinical awareness and offering practical insights for contemporary psychiatric practice. Across the chapters, themes that are directly relevant to daily clinical work are highlighted, including the importance of treatment continuity in psychotic disorders with recurrent courses, the assessment of prolonged and atypical dissociative phenomena, and the recognition and management of unexpected endocrine adverse effects emerging during psychopharmacological treatment. Each case serves as a focused reminder of the need for a comprehensive approach to the patient, systematic exclusion of medical etiologies when indicated, and close monitoring with thoughtful risk–benefit appraisal.

The purpose of case reporting is not to generalize from single experiences, but to share clinical reasoning, provide a structured perspective for colleagues who may encounter similar situations, and contribute modest yet meaningful observations to the literature. Accordingly, the chapters are organized to emphasize educational value by outlining clinical challenges, diagnostic uncertainty, and management considerations in a clear and practice-oriented manner.

We hope that this volume will be a useful resource for mental health professionals—particularly psychiatry trainees—by promoting systematic clinical assessment when faced with rare or

atypical presentations, bridging clinical intuition with evidence, and maintaining patient safety as the central priority.

Prof. Dr. MEHMET ASOĞLU

HARRAN ÜNİVERSİTESİ

İÇİNDEKİLER

GALACTORRHEA DEVELOPING AFTER TRAZODONE USE: A CASE REPORT 1

MEHMET ASOĞLU, ESAT SABUNCU

A SCHIZOPHRENIA CASE STABILIZED WITH TYPICAL AND ATYPICAL LONG-ACTING INJECTABLE ANTIPSYCHOTICS 7

MEHMET ASOĞLU, ESAT SABUNCU

DISSOCIATIVE IDENTITY DISORDER PRESENTING WITH PROLONGED DISSOCIATIVE AMNESIA AND IDENTITY ALTERATION: A CASE REPORT 12

MEHMET ASOĞLU, ESAT SABUNCU

BÖLÜM 1

Galactorrhea Developing After Trazodone Use: A Case Report

Mehmet ASOĞLU [1]
Esat SABUNCU[2],

1. Introduction

Antidepressants and Galactorrhea

Galactorrhea is defined as milk-like nipple discharge occurring outside of pregnancy and lactation, and it is frequently associated with hyperprolactinemia. In psychiatric practice, galactorrhea is most commonly observed as an adverse effect of antipsychotic medications; however, cases associated with antidepressants have been increasingly reported in the literature.[1]

Among antidepressants, agents with prominent serotonergic activity have been proposed to indirectly increase prolactin levels through dopaminergic inhibition.[2] Although galactorrhea cases

[1] Prof. Dr., Harran University Faculty of Medicine, Department of Psychiatry Orcid: 0000-0001-7515-7844
[2] Dr., Harran University Faculty of Medicine, Department of Psychiatry, Orcid: 0009-0006-8789-6082

related to selective serotonin reuptake inhibitors (SSRIs) and serotonin–norepinephrine reuptake inhibitors (SNRIs) have been reported, galactorrhea associated with trazodone use is a rarely documented adverse effect.[3]

Trazodone is an antidepressant that is often utilized at low doses primarily for its sedative and anxiolytic effects and exerts its action through 5-HT_2A antagonism and inhibition of serotonin reuptake. Although it has been suggested that trazodone may affect prolactin levels via indirect effects on the dopaminergic system, the underlying mechanism has not been clearly established.[4]

In this case report, we present a woman followed for depression and somatization disorder who developed galactorrhea after initiation of low-dose trazodone; differential diagnosis, possible mechanisms, and clinical management are discussed.

2. Case

This case report describes the clinical course of a 56-year-old woman who had been followed in an outpatient psychiatric clinic for longstanding depression and somatization disorder and developed galactorrhea following trazodone use during pharmacological treatment.

Patient Information

F.Ç. is a 56-year-old postmenopausal woman, married, primary school graduate, living with her family. She is not actively employed. According to the history obtained, she has been followed in the psychiatry outpatient clinic for approximately 6 years due to depressive symptoms and somatic complaints.

Psychiatric History and Treatment Course

The patient had been followed with diagnoses of Major Depressive Disorder and Somatization Disorder and had been using duloxetine 60 mg/day for a long period. Due to insomnia accompanying depressive symptoms, trazodone 50 mg/day was added to her treatment regimen.

Approximately 3 weeks after the initiation of trazodone, the patient noticed spontaneous, milk-like discharge from both breasts and therefore presented to the outpatient clinic.

Apart from galactorrhea, the patient did not report breast pain, visual field defects, headache, or menstrual irregularity.

Past Medical and Family History

No prior use of antipsychotic medication

No alcohol or substance use

Smokes (20 pack-years)

No known endocrine disease

Laboratory Findings

Laboratory evaluation revealed:

Serum prolactin level: 64 µg/L

TSH and fT4: within normal limits

Renal and liver function tests: within normal limits

Mental Status Examination

General appearance: consistent with stated age, establishes eye contact, self-care preserved

Mood: depressed

Affect: anxious

Thought content: somatically focused thoughts

Hallucinations: not reported

Insight: present

Clinical Assessment and Follow-up

The clinical presentation was considered to represent a trazodone-related adverse drug effect given that:

galactorrhea emerged after trazodone initiation,

there was no prior history of a similar adverse effect, and

no other organic cause was identified.

Accordingly:

trazodone was discontinued,

duloxetine was continued.

Within 2 weeks after discontinuation of trazodone, galactorrhea regressed and prolactin levels returned to normal.

3. Conclusion

This case is noteworthy in demonstrating galactorrhea, a rare adverse effect associated with trazodone use. Although trazodone is often considered a relatively safe agent at low doses, it should be kept in mind that it may influence prolactin regulation via its serotonergic effects.

In chronic conditions such as depression and somatization disorder, it is important to closely monitor adverse effects of adjunctive treatments and not to attribute somatic complaints solely to psychogenic causes. This case emphasizes that medications should always be considered in the differential diagnosis of

endocrine adverse effects occurring during antidepressant therapy. Current clinical practice guidelines of the Endocrine Society clearly emphasize that after excluding an underlying endocrine pathology, the first and most effective approach in cases of drug-induced hyperprolactinemia and galactorrhea is discontinuation or switching of the responsible agent.[5]

References

Bhattacharjee, S., Biswas, R., & Mandal, N. (2021). Selective serotonin reuptake inhibitor-induced galactorrhea with hyperprolactinemia. Indian journal of psychiatry, 63(6), 613–616. https://doi.org/10.4103/indianjpsychiatry.indianjpsychiatry_206_21

Torre, D. L., & Falorni, A. (2007). Pharmacological causes of hyperprolactinemia. Therapeutics and clinical risk management, 3(5), 929–951.

Arslan, F. C., Uysal, E. K., Ozkorumak, E., & Tiryaki, A. (2015). Trazodone induced galactorrhea: a case report. General hospital psychiatry, 37(4), 373.e1–373.e3732. https://doi.org/10.1016/j.genhosppsych.2015.04.002

Stahl SM. *Stahl's Essential Psychopharmacology: Neuroscientific Basis and Practical Applications*. 5th ed. Cambridge University Press; 2021.

Melmed, S., Casanueva, F. F., Hoffman, A. R., Kleinberg, D. L., Montori, V. M., Schlechte, J. A., Wass, J. A., & Endocrine Society (2011). Diagnosis and treatment of hyperprolactinemia: an Endocrine Society clinical practice guideline. The Journal of clinical endocrinology and metabolism, 96(2), 273–288. https://doi.org/10.1210/jc.2010-1692

BÖLÜM 2

A Schizophrenia Case Stabilized with Typical and Atypical Long-Acting Injectable Antipsychotics

Mehmet ASOĞLU [1]
Esat SABUNCU[2],

1. Introduction

A substantial proportion of relapses in schizophrenia spectrum disorders is associated with nonadherence and interruptions in treatment continuity. Therefore, long-acting injectable (LAI) antipsychotics have gained prominence—particularly in clinical contexts where regular oral medication intake cannot be maintained—due to their potential to reduce relapse risk and prevent hospitalization. The American Psychiatric Association (APA) guideline recommends considering LAI antipsychotic treatment when the patient prefers LAIs or when adherence is poor or uncertain.[1]

[1] Prof. Dr., Harran University Faculty of Medicine, Department of Psychiatry Orcid: 0000-0001-7515-7844
[2] Dr., Harran University Faculty of Medicine, Department of Psychiatry, Orcid: 0009-0006-8789-6082

Meta-analytic evidence indicates that LAI antipsychotics may confer advantages over oral antipsychotics in outcomes such as relapse and hospitalization.[2]

However, antipsychotic polypharmacy (especially the concomitant use of two LAIs) is not considered a routine guideline-based strategy; rather, it may be contemplated in selected cases based on prior treatment response and careful risk–benefit assessment, with close monitoring for adverse effects.[3]

2. Case

A 31-year-old Syrian woman, married with one child, was referred to our clinic from an external center due to approximately one year of persecutory, referential, and jealousy delusions; disorganized speech and behavior; marked suspiciousness; and deterioration in functioning and self-care.

Psychiatric History and Presentation

According to collateral history obtained from a relative, the patient had previously achieved significant clinical improvement with aripiprazole LAI 400 mg/month plus zuclopenthixol decanoate 200 mg/month. However, she had been unable to access her injection treatment and had therefore discontinued medications for the past three months. Following discontinuation, a gradual increase in positive psychotic symptoms, decline in social and occupational functioning, and marked reduction in self-care were reported.

Clinical Assessment and Inpatient Course

The patient was admitted to our inpatient unit, and the prior effective regimen—aripiprazole LAI 400 mg/month and zuclopenthixol decanoate 200 mg/month—was re-initiated. During initiation/re-initiation of aripiprazole LAI, short-term oral aripiprazole supplementation is recommended in accordance with

product information; therefore, oral aripiprazole 20 mg/day was added for 15 days.

Chlorpromazine 100 mg/day was started for comorbid insomnia.

During hospitalization, a partial reduction in psychotic symptoms was observed, including decreased suspiciousness and agitation and partial attenuation of delusional preoccupation. However, the patient's relatives requested discharge against medical advice ("treatment refusal"), and discharge procedures were completed accordingly.

Follow-up

In post-discharge follow-up, the patient remained clinically stable on aripiprazole LAI 400 mg/month plus zuclopenthixol decanoate 200 mg/month. No extrapyramidal side effects (akathisia, dystonia, rigidity) were detected. Her functioning was noted to improve substantially with ongoing treatment.

3. Discussion

This case is noteworthy in illustrating that, in a patient previously stabilized on LAI antipsychotic treatment, interruption of medication access (for three months) may be followed by exacerbation of psychotic symptoms, and that returning to the same LAI regimen may lead to partial and subsequently marked clinical improvement. The APA guideline emphasizes LAI antipsychotics as a strong option when preference is present or adherence is poor/uncertain.[1] Moreover, recent reviews and meta-analyses support that LAI antipsychotics may be advantageous compared with oral treatments regarding relapse and hospitalization outcomes.[2,4] In this context, the relapse in our case was considered more likely attributable to disruption in treatment continuity rather than insufficient treatment efficacy.

One distinctive aspect of this case is prior stabilization with a combination of two different LAI antipsychotics (aripiprazole LAI and zuclopenthixol decanoate). Although antipsychotic polypharmacy can occur in clinical practice, its evidence base remains limited; therefore, it generally requires careful justification (e.g., prior response patterns, failure of monotherapies, adverse-effect profile considerations) and close monitoring.[3]

In addition, the patient's refugee/migrant status provides a critical context in which language barriers and systemic access limitations may adversely affect treatment continuity. The World Health Organization (WHO) has noted that language barriers and difficulties accessing services can restrict access to mental health care.[5] Accordingly, when planning LAI treatment, ensuring "continuity of access and administration" (e.g., appointment logistics, injection sites, social support, interpreter needs, health coverage/transportation) should be considered an integral component of clinical decision-making.

In conclusion, this case highlights that: (i) LAI antipsychotics may be an important tool for relapse prevention, particularly when adherence is fragile; (ii) interruptions in access to treatment may lead to marked clinical deterioration within a short period; and (iii) a dual-LAI strategy should be considered only in selected cases, with recognition of limited evidence and under close monitoring.

References

Keepers, G. A., Fochtmann, L. J., Anzia, J. M., Benjamin, S., Lyness, J. M., Mojtabai, R., Servis, M., Walaszek, A., Buckley, P., Lenzenweger, M. F., Young, A. S., Degenhardt, A., Hong, S. H., & (Systematic Review) (2020). The American Psychiatric Association Practice Guideline for the Treatment of Patients With Schizophrenia. *The American journal of psychiatry*, *177*(9), 868–872. https://doi.org/10.1176/appi.ajp.2020.177901

Kishimoto, T., Hagi, K., Kurokawa, S., Kane, J. M., & Correll, C. U. (2021). Long-acting injectable versus oral antipsychotics for the maintenance treatment of schizophrenia: a systematic review and comparative meta-analysis of randomised, cohort, and pre-post studies. *The lancet. Psychiatry*, *8*(5), 387–404. https://doi.org/10.1016/S2215-0366(21)00039-0

Cipolla, S., Catapano, P., D'Amico, D., Monda, R., Sallusto, N. P., Perris, F., De Santis, V., Catapano, F., Luciano, M., & Fiorillo, A. (2024). Combination of Two Long-Acting Antipsychotics in Schizophrenia Spectrum Disorders: A Systematic Review. *Brain sciences*, *14*(5), 433. https://doi.org/10.3390/brainsci14050433

Kane, J. M., & Rubio, J. M. (2023). The place of long-acting injectable antipsychotics in the treatment of schizophrenia. *Therapeutic advances in psychopharmacology*, *13*, 20451253231157219. https://doi.org/10.1177/20451253231157219

Öztürk, G., Timarcioğlu, K., Dikeç, G., Karali, E., Nacaroğlu, H., Çakir, H., & Harmanci Seren, A. K. (2024). Syrian refugees' experiences while receiving mental health services and psychiatric nursing care: A qualitative study. *Journal of advanced nursing*, *80*(4), 1511–1522. https://doi.org/10.1111/jan.15894

BÖLÜM 3

Dissociative Identity Disorder Presenting with Prolonged Dissociative Amnesia and Identity Alteration: A Case Report

Mehmet ASOĞLU [1]
Esat SABUNCU[2],

1. Introduction

Dissociative disorders are psychiatric conditions characterized by disruptions in the integration of consciousness, memory, identity, and perception, and are frequently associated with trauma.[1] Dissociative Identity Disorder (DID) is defined by the presence of two or more distinct identity states and recurrent episodes of amnesia associated with transitions between these identity states.[2] In clinical practice, dissociative symptoms often remit within hours or days; however, dissociative presentations lasting for weeks have been reported only rarely.[3]

Excluding organic etiologies is critical in the diagnosis of dissociative disorders.[4] In particular, metabolic disorders such as

[1] Prof. Dr., Harran University Faculty of Medicine, Department of Psychiatry Orcid: 0000-0001-7515-7844
[2] Dr., Harran University Faculty of Medicine, Department of Psychiatry, Orcid: 0009-0006-8789-6082

Wilson's disease—which may involve the central nervous system—necessitate careful differential diagnosis of psychiatric symptoms.[5] In this case report, we present a patient with Wilson's disease who exhibited approximately 50 days of dissociative amnesia and identity alteration despite the absence of detectable organic pathology.

2. Case Presentation

A 30-year-old woman with a known diagnosis of Wilson's disease followed by gastroenterology had been under follow-up at an external center with a diagnosis of depression. She presented to our outpatient psychiatry clinic with complaints of memory loss persisting for the past 25 days, inability to recognize family members, claiming to be someone else, marked personality change, and recurrent suicide attempts.

Following the initial psychiatric evaluation, a neurology consultation was obtained. Detailed neurological examination, brain imaging, and laboratory investigations revealed no acute or progressive organic pathology. The patient was subsequently admitted to the psychiatry ward for inpatient observation and treatment.

On comprehensive mental status examination, she demonstrated impaired orientation to time and person, failure to recognize family members, insistence that she had a different identity, extensive amnesia regarding her personal history, and labile affect. No persistent delusional structure suggestive of a primary psychotic disorder was identified. The overall clinical picture was considered consistent with Dissociative Identity Disorder.

Treatment was initiated with venlafaxine 75 mg/day, mirtazapine 30 mg/day, and lorazepam 2.5 mg/day. In addition to pharmacotherapy, hypnosis sessions were conducted, and—based on clinical necessity—six sessions of electroconvulsive therapy (ECT) were administered. During this period, the patient was closely

monitored by gastroenterology for Wilson's disease, and her ongoing medical treatment was adjusted as needed.

Although dissociative amnesia and identity alteration persisted for approximately 50 days, gradual improvement in memory functions, restoration of identity integration, and reduction in suicidal ideation were observed during the later phases of treatment. After achieving full clinical remission, the patient was discharged, and a post-discharge follow-up plan was established.

3. Discussion

This case is notable for an unusually prolonged dissociative presentation within the clinical spectrum of dissociative disorders. The literature indicates that dissociative amnesia and identity alterations are typically short-lived, whereas cases persisting for weeks have been reported only in limited numbers.[3],[6]

The presence of a metabolic disorder such as Wilson's disease—known to manifest with neurological and psychiatric symptoms—further complicates the differential diagnosis.[5] However, the absence of pathological findings in neurological assessments in this case supported a primary psychiatric origin of the dissociative presentation.[4]

The combined use of pharmacotherapy, hypnotherapy, and ECT appears to have contributed to clinical improvement. The literature includes limited reports suggesting that ECT may be beneficial in severe and treatment-resistant dissociative cases.[7]

This case is clinically important in demonstrating that DID may present with dissociative periods of an atypically long duration. Particularly in patients with comorbid medical conditions, a comprehensive approach should be adopted in the diagnosis and treatment of dissociative disorders after organic causes have been carefully excluded.

Early recognition of prolonged dissociative states, timely initiation of appropriate pharmacological and psychotherapeutic interventions, and—when indicated—consideration of advanced treatment options such as ECT may substantially improve prognosis. This case underscores that dissociative disorders can follow courses that differ from expectations in both duration and severity, thereby providing clinically meaningful awareness for practitioners.

References

Spiegel, D., Lewis-Fernández, R., Lanius, R., Vermetten, E., Simeon, D., & Friedman, M. (2013). Dissociative disorders in DSM-5. *Annual review of clinical psychology*, *9*, 299–326. https://doi.org/10.1146/annurev-clinpsy-050212-185531

American Psychiatric Association. *DSM-5-TR: Diagnostic and Statistical Manual of Mental Disorders*. 2022.

Brand, Bethany & Loewenstein, Richard. (2010). Dissociative Disorders: An Overview of Assessment, Phenomonology and Treatment.. Psychiatric Times.

Staniloiu, A., & Markowitsch, H. J. (2014). Dissociative amnesia. *The lancet. Psychiatry*, *1*(3), 226–241. https://doi.org/10.1016/S2215-0366(14)70279-2

Dening, T. R., & Berrios, G. E. (1989). Wilson's disease. Psychiatric symptoms in 195 cases. *Archives of general psychiatry*, *46*(12), 1126–1134. https://doi.org/10.1001/archpsyc.1989.01810120068011

Dorahy, M. J., Brand, B. L., Sar, V., Krüger, C., Stavropoulos, P., Martínez-Taboas, A., Lewis-Fernández, R., & Middleton, W. (2014). Dissociative identity disorder: An empirical overview. *The Australian and New Zealand journal of psychiatry*, *48*(5), 402–417. https://doi.org/10.1177/0004867414527523

Bowman, E. S., & Coons, P. M. (1992). The use of electroconvulsive therapy in patients with dissociative disorders. *The Journal of nervous and mental disease*, *180*(8), 524–528. https://doi.org/10.1097/00005053-199208000-00008

BİDGE